PEDIATRICS®

OFFICIAL JOURNAL OF THE AMERICAN ACADEMY OF PEDIATRICS

Prolonged Rate-Corrected QT Interval and Other Electrocardiogram Abnormalities in Girls With Turner Syndrome

Carolyn A. Bondy, Irene Ceniceros, Phillip L. Van, Vladimir K. Bakalov and Douglas R. Rosing

Pediatrics 2006;118;1220-1225
DOI: 10.1542/peds.2006-0776

This information is current as of October 10, 2006

The online version of this article, along with updated information and services, is located on the World Wide Web at:
http://www.pediatrics.org/cgi/content/full/118/4/e1220

PEDIATRICS is the official journal of the American Academy of Pediatrics. A monthly publication, it has been published continuously since 1948. PEDIATRICS is owned, published, and trademarked by the American Academy of Pediatrics, 141 Northwest Point Boulevard, Elk Grove Village, Illinois, 60007. Copyright © 2006 by the American Academy of Pediatrics. All rights reserved. Print ISSN: 0031-4005. Online ISSN: 1098-4275.

American Academy of Pediatrics
DEDICATED TO THE HEALTH OF ALL CHILDREN™

Downloaded from www.pediatrics.org at Natl Inst Of Hlth Library on October 10, 2006

Prolonged Rate-Corrected QT Interval and Other Electrocardiogram Abnormalities in Girls With Turner Syndrome

Carolyn A. Bondy, MD[a], Irene Ceniceros, MS[a], Phillip L. Van, MS[a], Vladimir K. Bakalov, MD[a], Douglas R. Rosing, MD[b]

[a]Developmental Endocrinology Branch, National Institute of Child Health, National Institutes of Health, Bethesda, Maryland; [b]National Heart, Lung and Blood Institute, National Institutes of Health, Bethesda, Maryland

The authors have indicated they have no financial relationships relevant to this article to disclose.

ABSTRACT

BACKGROUND. We recently reported that electrocardiographic abnormalities are common in adults with monosomy X (Turner syndrome), but this issue has not been investigated in girls with Turner syndrome.

PATIENTS AND METHODS. We analyzed electrocardiograms in 78 girls with Turner syndrome and 50 age-matched control girls. The girls with Turner syndrome had additional cardiac and metabolic evaluations.

RESULTS. Girls with Turner syndrome were more likely to demonstrate ≥1 electrocardiographic findings including right axis deviation, right ventricular hypertrophy, accelerated atrioventricular conduction, T-wave abnormalities, and a prolonged rate-corrected QT interval. The right-sided findings were associated with partial anomalous pulmonary venous connection, but the etiology of the other findings remains unknown. The rate-corrected QT interval was significantly longer in girls with Turner syndrome (431 ± 22 vs 407 ± 21 milliseconds). Twenty-eight girls with Turner syndrome but only 2 controls had a rate-corrected QT interval above the reference range. We found no correlation between body habitus, cardiac dimensions, or metabolic parameters and the rate-corrected QT interval duration in girls with Turner syndrome.

CONCLUSIONS. Cardiac conduction and repolarization abnormalities seem to affect both young girls and adults with Turner syndrome equally, suggesting that electrophysiologic defects are intrinsic to the syndrome and indicating that electrocardiogram analysis should be included in evaluating and monitoring even the youngest patients with Turner syndrome. Attention to the rate-corrected QT interval is important, because some common medications may further prolong this interval and increase the risk of arrhythmias.

www.pediatrics.org/cgi/doi/10.1542/peds.2006-0776

doi:10.1542/peds.2006-0776

Key Words
electrophysiology, Turner syndrome, heart disease, long QT

Abbreviations
TS—Turner syndrome
BAV—bicuspid aortic valve
Coarc—coarctation of the aorta
RAD—right axis deviation
QTc—rate-corrected QT interval
ECG—electrocardiogram
NIH—National Institutes of Health
LVM—left ventricular mass
PAPVR—partial anomalous pulmonary venous return

Accepted for publication Jun 29, 2006

Address correspondence to Carolyn A. Bondy, MD, Developmental Endocrinology Branch, National Institute of Child Health and Human Development, NIH, Building 10 CRC, Room 1-3330, Bethesda, MD 20892-1103. E-mail: bondyc@mail.nih.gov

PEDIATRICS (ISSN Numbers: Print, 0031-4005; Online, 1098-4275); published in the public domain by the American Academy of Pediatrics

Downloaded from www.pediatrics.org at Natl Inst Of Hlth Library on October 10, 2006

TURNER SYNDROME (TS), caused by partial or complete absence of a second sex chromosome, affects ~1 in 2000 live female births.[1] The most common features include short stature, premature ovarian failure, and congenital cardiovascular defects.[2] The most common congenital heart defects include elongated transverse arch of the aorta (~50%),[3] bicuspid aortic valve (BAV), and coarctation of the aorta (Coarc), which affect ~15% to 20% and 10% to 12% of patients, respectively.[4–6] Less common defects include persistent left superior vena cava and partial anomalous venous return (~13% each),[3,7] with septal defects or other anomalies being much less common. We recently showed that adults with TS have marked cardiac electrophysiological abnormalities apart from the presence of anatomic defects.[8] The abnormalities included right axis deviation (RAD), accelerated atrioventricular conduction, and T-wave abnormalities. The PR interval was significantly shorter and the rate-corrected QT interval (QTc) significantly longer in women with TS.

We did not find any associations between body habitus, cardiac dimensions, or metabolic parameters and the incidence of electrocardiogram (ECG) abnormalities or QTc duration in adults with TS.[8] The ECG abnormalities described in adults with TS are consistent with recent research showing that genetic defects leading to congenital abnormalities of cardiovascular development may also be associated with diffuse myopathic changes accompanied by conduction defects in adults apart from the presence or repair of congenital heart defects.[9] In this study we extended our investigation of ECG abnormalities to young girls with TS and age-matched controls.

PATIENTS AND METHODS

Study Subjects

This study included the first 78 girls with TS (aged 7–17) who enrolled in a National Institute of Child Health and Human Development Institutional Review Board–approved protocol. They were recruited through National Institute of Child Health and Human Development (http://turners.nichd.nih.gov/ProtFrNewProtocols.html) and Turner Syndrome Society of the United States Web-site announcements between 2001 and 2005. These announcements did not specifically feature cardiovascular evaluation as part of the study. Parents or guardians signed informed-consent forms, and the study subjects signed informed-assent forms. The study was conducted at the National Institutes of Health (NIH) Clinical Research Center. Criteria to enroll in the TS study include a 50-cell karyotype by G-banding with >70% of cells showing absence or abnormality of the second sex chromosome. All subjects discontinued estrogen, growth hormone, and any other medications except for thyroid hormone during the study.

For comparison, we used ECGs from "normal" pediatric volunteers who were participants in various institutional review board–approved studies through the NIH Clinical Research Center. They were recruited through the NIH normal-volunteer–enrollment program and verified to be generally healthy. Fifty girls were selected on the basis of age matching to the girls with TS.

ECGs

Standard 12-lead ECGs were obtained by using Hewlett Packard Pagewriter machines (Palo Alto, CA). All ECGs were recorded at 25 mm/second with an amplitude of 1 mV/10 mm and 60-Hz filtering. They were analyzed by using Pagewriter ECG-analysis software (Philips Medical Systems, Bothell, WA). The QT-interval measurement in this program is made by averaging the 5 longest QT intervals with T-wave amplitude >0.15 mV. All ECGs were overread by a single cardiologist (D.R.R.) who was blinded to subject allocation (TS versus control).

ECG Interpretation

- Normal PR interval: 90 to 170 milliseconds for 7- to 15-year-olds and 120 to 200 milliseconds for ≥16-year-olds[10]
- Normal QRS duration: 40 to 90 milliseconds for 7- to 15-year-olds and 50 to 100 milliseconds for ≥16-year-olds[11]
- Normal QTc: ≤440 milliseconds[11,12]
- Abnormal ST segment: ≥1-mm ST depression 80 milliseconds after the J point
- Abnormal T waves: limb leads − QRS-T angle >60°, precordium − T < 10% of the height of the QRS or negative in configuration (in V4–V6)
- Left axis deviation: QRS axis in the limb leads less than −15°
- RAD: QRS axis in the limb leads >110°
- Poor R-wave progression: failure of R waves to increase in amplitude in any 2 consecutive leads V1 to V3
- Early transition: R/S ratio > 1 in lead V2
- Late transition: R/S ratio < 1 in lead V5
- Left ventricular hypertrophy: RV6 taller than 95% and SV1 deeper than 95% of normal[12]
- Right ventricular hypertrophy: RV1 taller than 95% plus SV6 deeper than 95% of normal, or R′ > R in V1 and V2 without widening of QRS complex, or qR in V1 and V2, or pure R wave in V1 and V2, with or without ST and T changes indicative of strain[12]
- Left atrial abnormality: terminal negativity of P wave in V1 at least 0.1 mV in depth and 40 milliseconds in width
- Right atrial abnormality: P wave in lead II ≥ 0.25 mV

Downloaded from www.pediatrics.org at Natl Inst Of Hlth Library on October 10, 2006

- Low voltage: all limb leads <0.5 mV or all precordial leads <1.0 mV

Echocardiogram for Left Ventricular Mass Assessment

All subjects underwent transthoracic two-dimensional and Doppler echocardiography using commercially available echocardiography machines. Standard parasternal, apical, and subcostal views were acquired with the patients in the left lateral recumbent position and stored digitally and on VHS videotape for analysis. Evaluation of the echo images was performed while blind to each subject's clinical presentation and past cardiovascular history. Cardiac measurements were performed according to American Society of Echocardiography guidelines.[13] Left ventricular mass (LVM) was calculated by using an anatomically validated formula: LVM (g) = 0.8 [1.04 (IVS + PW + LVIDD^3 − (LVIDD)^3] + 0.6 (IVS indicates interventricular septal thickness; PW, posterior wall thickness; LVIDD, left ventricular internal diastolic dimension).[14]

Laboratory Tests

Routine fasting blood chemistries including glucose, electrolytes, minerals, lipids, and thyroid tests were obtained for each subject with TS. These assays have been described (see the NIH Clinical Center Lab Directory Web site at http://cclnprod.cc.nih.gov/dlm/testguide.nsf/Index?OpenForm).

Statistics

Continuous data are expressed as means with SDs and nominal data as numbers and percent. Comparisons between group means were by 1-way analysis of variance/analysis of covariance with Fisher's protected least-significant difference. Associations were tested by χ^2 analysis. Correlations were tested by regression analysis. All analyses were performed by using StatView 5.0.1 for Windows (SAS Institute, Inc, Cary, NC).

RESULTS

The average age of the girls with TS was 12.9 ± 2.3 years and of normal controls was 12.5 ± 2.9 years (range: 7–17 years for both groups). As expected, average height was less in the TS group: 137 ± 13 vs 158 ± 11 cm for controls. Average BMI was also less in the TS group: 22 ± 5 vs 30 ± 11 kg/m^2 for controls. The karyotype distribution for girls with TS is shown in Table 1.

ECG Findings in TS Versus 46,XX Age-Matched Controls

Girls with TS were almost twice as likely to have an abnormal ECG as controls (53.8% vs 30%; P = .008) (Table 2). The major findings in the girls with TS included RSR′ (an initial R wave, followed by an S wave, then another often-large R wave in right-sided leads, associated with right bundle branch block), RAD, right ventricular hypertrophy, T-wave abnormalities, accelerated atrioventricular conduction, and prolonged QTc.

TABLE 1 **Karyotype Distribution in Subjects With TS**

No.	Karyotype	% of Total	% Normal Cells
32	45,X	41	0
10	45,X/46,XiXq	13	0
9	45,X/46,XrX	12	0
7	45,X/46,XX	8	<12
4	46,XdelXp	5	0
3	46,XiXq	4	0
3	46,XderX[a]	4	0
3	45X/46,XY	4	<30
2	46,XdelXq	2	0
3	45,X/47,XXX	4	0
2	45,X/46,XdelXq	2	0

Karyotyping was performed on at least 50 lymphocytes by G-banding.
[a] Three individuals had translocation of the long arm of one X chromosome to an autosome; these were "effective" p deletions.

There were marked differences in ECG intervals in girls with TS compared with normal controls (Table 2). The PR interval was significantly shorter and the QTc was significantly longer in those with TS (Fig 1). Twenty-eight girls with TS (36%) but only 2 controls (4%) had a QTc above the reference range (>440 milliseconds; P = .0001). Multiple-regression analysis showed that neither height nor BMI contributed significantly to variation in PR interval or QTc in these 2 groups of children. The girls with TS had a significantly higher heart rate than those in the control group (Table 2). However, the difference in the QTc was not explained by the higher heart rate in those with TS. When we plotted heart rate versus QTc duration for the 2 groups, there were 2 parallel regression lines, with the TS line shifted upward, with a longer QTc for every heart compared with control (data not shown), Moreover, we selected heart rate–matched subgroups in which the heart rate in those with TS was 81.7 (SD: 5.4) beats per minute and for controls was 81.2 (SD: 5.4) beats per minute (P = .7). In these heart rate–matched groups, the TS group's mean QTc was 428.5 (SD: 20) vs 409.8 (SD: 15) milliseconds for controls (P = .001).

Karyotype, Metabolic Factors, and ECG Findings in Girls With TS

ECG abnormalities and QTc prolongation were not more common in 100% 45,X patients compared with the rest of the karyotypes taken together (data not shown). It should be noted that the number of individuals with a normal cell line in our study population was small, and these girls had a very small proportion of normal cells. The great majority of subjects with TS were monosomic for Xp in all of the cells in their 50-lymphocyte karyotype (Table 1). Thus, these girls may be more seriously affected by haploinsufficiency for important X-linked

Downloaded from www.pediatrics.org at Natl Inst Of Hlth Library on October 10, 2006

TABLE 2 **ECGs in Girls With TS**

	TS (78)	Controls (50)	*P*
ECG abnormalities, *n* (%)			
RSR′	6 (7.7)	2 (4)	NS
RAD	6 (7.7)	0 (0)	.045 (χ^2; = 4.0)
LAD	1 (1.3)	0 (0)	NS
LVH	1 (1.3)	1 (2)	NS
RVH	3 (3.8)	1 (2)	NS
Early precordial transition	2 (2.7)	0 (0)	NS
Late precordial transition	2 (2.7)	0 (0)	NS
T wave	8 (10.2)	3 (6.0)	NS
Ectopic SV rhythm	5 (6.4)	1 (2)	NS
Short PR interval[a]	4 (5.1)	1 (2)	NS
Long PR interval	0 (0)	2 (4)	NS
Prolonged QRS[b]	11 (14)	6 (12)	NS
QTc > 440 ms	28 (35.9)	2 (4)	.0001 (χ^2; = 17)
Any ECG abnormality	42 (53.8)	15 (30)	.008 (χ^2; = 7.0)
Intervals, mean ± SD			
Heart rate, beats per min	91 ± 15	76 ± 11	<.0001
PR, ms	127 ± 16	144 ± 26	<.0001
QRS, ms	83 ± 9	81 ± 8	.28
QT, ms	353 ± 32	369 ± 28	<.0034
QTc, ms	431 ± 22	407 ± 21	<.0001

Numbers of "ECG abnormalities" are compared by χ^2. The data for intervals are means with SD, compared by ANOVA. NS indicates not significant; LAD, left axis deviation; LVH, left ventricular hypertrophy; RVH, right ventricular hypertrophy; SV, supraventricular.

[a] PR < 0.12 ms.

[b] QRS > 0.12 ms.

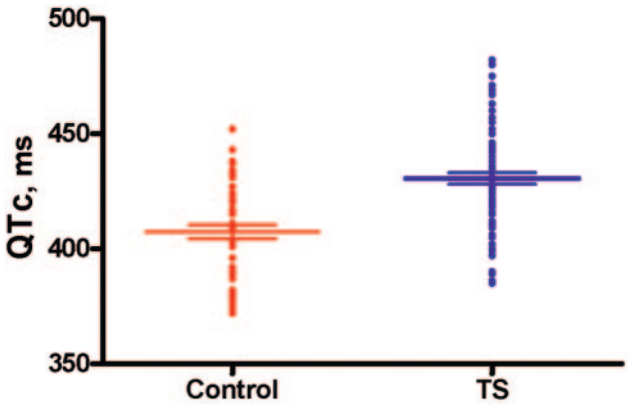

FIGURE 1
Distribution of QTc in normal girls aged 7 to 17 years (control) and girls of the same age with TS. The wide bars indicate the median, and the 2 smaller bars show ±SEM.

genes than the average clinic population of patients with TS.

Metabolic factors including hyperglycemia, thyroid, electrolyte, or mineral abnormalities may contribute to ECG abnormalities and QTc prolongation. However, results of fasting glucose tests, K^+, Ca^{2+}, and Mg^{2+} levels, and thyroid-function tests were within the reference range for all girls with TS.

Cardiovascular Abnormalities and ECG Findings in Girls With TS

Blood pressure was normal in all but 1 girl with TS, and her ECG was normal. There was no significant correlation between systolic or diastolic blood pressure and PR-interval or QTc variation. We analyzed the contribution of left ventricular wall thickness and mass to QTc duration variation. There was no correlation between wall thickness or LVM and QTc (eg, for LVM, $R^2 = 0.009$; $P = .44$).

We evaluated ECG findings in girls with a BAV with or without Coarc. (All girls with Coarc had undergone a successful surgical repair.) Girls with BAV ± Coarc ($n = 22$) were more likely to have a longer QTc compared with girls with TS who had apparently normal hearts and aorta ($n = 56$), although group means were not significantly different (434 ± 25 vs 429 ± 21 milliseconds; $P = .3$). The mean QRS duration, however, was longer in the BAV ± Coarc group (87 ± 8 vs 82 ± 9 milliseconds; $P = .02$).

Three girls in this study had partial anomalous pulmonary venous return (PAPVR); 2 of which had both RAD and RVH, and 1 had isolated RAD. The 3 other girls with RAD had no detectable cardiovascular abnormality.

DISCUSSION

This study documents the presence of previously unrecognized cardiac conduction and repolarization abnormalities in girls with TS. Girls with TS are more likely to have abnormal ECG readings, including RSR′ complexes, RAD, right ventricular hypertrophy, accelerated atrioventricular conduction, T-wave abnormalities, and prolonged QTc duration compared with age-matched normal girls. These findings are not associated with small stature, hypertension, cardiac hypertrophy, or metabolic

Downloaded from www.pediatrics.org at Natl Inst Of Hlth Library on October 10, 2006

factors, suggesting that cardiac conduction and repolarization abnormalities are intrinsic features of TS.

Our findings in young girls with TS are similar to previous findings for adult women with TS.[8] In that study, we compared ECGs in 100 women with TS and 100 controls. The adults (average age: 35 years; range: 18–59 years) were far more likely to have RAD, accelerated atrioventricular conduction, and T-wave abnormalities than age-matched control women—the same abnormalities defined in this study of girls aged 7 to 17 years. In addition, adults with TS had significantly longer QTc compared with normal controls. In fact, the average QTc of adults was 423 ± 19 milliseconds compared with the girls' average of 431 ± 22 milliseconds. These findings in both children and adults with TS are indicative of an intrinsic abnormality of the cardiac conduction/repolarization system that affects one third of individuals with TS.

RAD, or left posterior fascicular block, is an uncommon ECG finding in the normal population. In adults this finding typically signifies chronic lung disease, RVH, and coronary artery disease. In our healthy young group, chronic lung disease and coronary disease were not contributors to this finding. Of the 6 girls with TS with RAD, 3 met voltage criteria for RVH, identifying right heart strain as the likely cause of the axis deviation. Two of these girls had known PAPVR, which likely accounts for this pattern. Another girl with isolated RAD also had PAPVR. The other 3 girls with RAD had no apparent cardiovascular disease on routine echocardiography. An RSR′ pattern in V1 was also more common in girls with TS than in normal girls. It is possible that that the constellation of RSR′, RAD, and RVH in girls and women with TS hints at congenital cardiovascular defects that may escape detection by routine noninvasive studies.

The accelerated atrioventricular conduction (short PR interval) and QTc prolongation found in girls and women with TS could be caused by intrinsic electrical properties of the heart or altered input from the autonomic nervous system. Other congenital long-QT syndromes are caused by mutations/deletions of genes encoding ion-channel components.[15] It is possible that haploinsufficiency of unknown, X-linked gene(s) underlies these electrophysiologic findings that affected approximately one third of our patients with TS. Fetal lymphedema might impact the embryonic myocardium and conducting system. Alternatively, an autonomic defect (eg, enhanced catecholaminergic tone or decreased parasympathetic activity) may contribute to the relative tachycardia, shortened PR interval, and prolonged QTc found in TS.[16,17] Acquired long-QT syndromes may be caused by drugs, ischemic or hypertrophic heart disease, and autonomic neuropathy,[15] but none of these factors explain the findings in our TS study group.

There is an association between the length of the QTc and mortality in adults.[12,18–22] This correlation may be attributed to the hypertension or coronary disease associated with QTc prolongation in many older adults. However, a recent study that controlled for such contributory conditions found an increased risk for sudden death beginning with a QTc of >440 milliseconds.[22] Because almost one third of girls and 21% of women with TS in our NIH study population have a QTc of >440 milliseconds, this raises important considerations for their caregivers. Women with TS are at increased risk of cardiac mortality,[5,23,24] which may be a result of the long-term consequences of congenital anatomic defects such as BAV, aortic aneurysm, dissection, or rupture. In addition, multiple risk factors for coronary artery disease, including hypertension,[25] atherogenic lipids,[26,27] and diabetes,[25] are increased as part of the syndrome; hence, myocardial infarction may also contribute to the increased cardiac mortality. The current studies showing prolongation of the QTc in young girls as well as adults with TS[8] raise the possibility that, in some circumstances, patients with TS may be at heightened risk for serious arrhythmia as well. It should be noted that our NIH TS study population comprises patients with high-grade X monosomy and very few individuals with normal cell lines, in contrast to many clinics in which a large proportion of patients with TS may have more extensive mosaicism for normal cell populations.

CONCLUSIONS

It is clear that we need additional investigation to determine the underlying cause and consequences of this prolonged QTc in patients with TS and to define appropriate treatment. In the meantime, it is important to obtain baseline ECG analysis as part of the initial evaluation of TS and to follow the ECG on a regular basis (eg, at the same intervals that echocardiograms are performed). In addition, it is probably wise to monitor ECGs in patients with TS when prescribing drugs associated with QTc prolongation. Some of the medications known to prolong the QT interval and induce torsades de pointes are erythromycin and congeners, antiarrhythmic agents, and major antipsychotic medications (an extensive listing of drugs that affect the QT interval is available online[28]). In addition, use of most stimulants is discouraged for children with congenital long-QT syndrome.

ACKNOWLEDGMENT

The intramural research program of the National Institute of Child Health and Human Development supported this work.

REFERENCES

1. Nielsen J, Wohlert M. Sex chromosome abnormalities found among 34,910 newborn children: results from a 13-year incidence study in Arhus, Denmark. *Birth Defects Orig Artic Ser.* 1990;26:209–223

Downloaded from www.pediatrics.org at Natl Inst Of Hlth Library on October 10, 2006

2. Ranke MB, Saenger P. Turner's syndrome. *Lancet.* 2001;358:309–314
3. Ho VB, Bakalov VK, Cooley M, Van PL, Hood MN, Burklow TR, Bondy CA. Major vascular anomalies in Turner syndrome: prevalence and magnetic resonance angiographic features. *Circulation.* 2004;110:1694–1700
4. Gotzsche CO, Krag-Olsen B, Nielsen J, Sorensen KE, Kristensen BO. Prevalence of cardiovascular malformations and association with karyotypes in Turner's syndrome. *Arch Dis Child.* 1994;71:433–436
5. Mazzanti L, Cacciari E. Congenital heart disease in patients with Turner's syndrome. Italian Study Group for Turner Syndrome (ISGTS). *J Pediatr.* 1998;133:688–692
6. Prandstraller D, Mazzanti L, Picchio F, et al. Turner's syndrome: cardiologic profile according to the different chromosomal patterns and long-term clinical follow-up of 136 nonpreselected patients. *Pediatr Cardiol.* 1999;20:108–112
7. Bechtold SM, Dalla Pozza R, Becker A, Meidert A, Dohlemann C, Schwarz HP. Partial anomalous pulmonary vein connection: an underestimated cardiovascular defect in Ullrich-Turner syndrome. *Eur J Pediatr.* 2004;163:158–162
8. Bondy CA, Van PL, Bakalov VK, et al. Prolongation of the cardiac QTc interval in Turner syndrome. *Medicine (Baltimore).* 2006;85:75–81
9. Pashmforoush M, Lu JT, Chen H, et al. Nkx2–5 pathways and congenital heart disease; loss of ventricular myocyte lineage specification leads to progressive cardiomyopathy and complete heart block. *Cell.* 2004;117:373–386
10. University of Chicago. Heart diseases in children. Available at: http://pediatriccardiology.uchicago.edu/Index.htm. Accessed August 14, 2006
11. Bazett J. An analysis of time relation of electrocardiograms. *Heart.* 1920;7:353–367
12. Brown D, Giles W, Greenlund K, Rodolfo V, Croft J. Impaired fasting glucose, diabetes mellitus, and cardiovascular disease risk factors are associated with prolonged QTc duration: results from the Third National Health and Nutrition Examination Survey. *J Cardiovasc Risk.* 2001;8:227–233
13. Schiller N, Shah P, Crawford M, et al. Recommendations for quantitation of the left ventricle by 2-dimensional echocardiography. American Society of Echocardiography Committee on Standards, Subcommittee on Quantitation of Two-dimensional Echocardiograms. *J Am Soc Echocardiogr.* 1989;2:358–367
14. Devereux R, Alonso D, Lutas E. Echocardiographic assessment of left ventricular hypertrophy: comparison to necropsy findings. *Am J Cardiol.* 1986;57:450–458
15. Leroy SS, Russell M. Long QT syndrome and other repolarization-related dysrhythmias. *AACN Clin Issues.* 2004;15:419–431
16. Lee S, Harris ND, Robinson RT, Yeoh L, Macdonald IA, Heller SR. Effects of adrenaline and potassium on QTc interval and QT dispersion in man. *Eur J Clin Invest.* 2003;33:93–98
17. Passino C, Franzoni F, Gabutti A, Poletti R, Galetta F, Emdin M. Abnormal ventricular repolarization in hypertensive patients: role of sympatho-vagal imbalance and left ventricular hypertrophy. *Int J Cardiol.* 2004;97:57–62
18. Linnemann B, Janka HU. Prolonged QTc interval and elevated heart rate identify the type 2 diabetic patient at high risk for cardiovascular death. The Bremen Diabetes Study. *Exp Clin Endocrinol Diabetes.* 2003;111:215–222
19. Robbins J, Nelson JC, Rautaharju PM, Gottdiener JS. The association between the length of the QT interval and mortality in the Cardiovascular Health Study. *Am J Med.* 2003;115:689–694
20. Okin PM, Devereux RB, Lee ET, Galloway JM, Howard BV. Electrocardiographic repolarization complexity and abnormality predict all-cause and cardiovascular mortality in diabetes: the strong heart study. *Diabetes.* 2004;53:434–440
21. Dekker JM, Crow RS, Hannan PJ, Schouten EG, Folsom AR. Heart rate-corrected QT interval prolongation predicts risk of coronary heart disease in black and white middle-aged men and women: the ARIC study. *J Am Coll Cardiol.* 2004;43:565–571
22. Straus SMJM, Kors JA, De Bruin ML, et al. Prolonged QTc Interval and Risk of Sudden Cardiac Death in a Population of Older Adults. *J Am Coll Cardiol.* 2006;47:362–367
23. Elsheikh M, Dunger DB, Conway GS, Wass JA. Turner's syndrome in adulthood. *Endocr Rev.* 2002;23:120–140
24. Gravholt CH, Juul S, Naeraa RW, Hansen J. Morbidity in Turner syndrome. *J Clin Epidemiol.* 1998;51:147–158
25. Nathwani NC, Unwin R, Brook CG, Hindmarsh PC. Blood pressure and Turner syndrome. *Clin Endocrinol (Oxf).* 2000;52:363–370
26. Van PL, Bakalov VK, Bondy CA. Monosomy for the X chromosome is associated with an atherogenic lipid profile. *J Clin Endocrinol Metab.* 2006; In press
27. Van PL, Bakalov VK, Zinn AR, Bondy CA. Maternal X chromosome, visceral adiposity, and lipid profile. *JAMA.* 2006;295:1373–1374
28. University of Arizona Health Sciences Center. Drug lists (by risk groups). Available at: www.arizonacert.org. Accessed August 14, 2006

Downloaded from www.pediatrics.org at Natl Inst Of Hlth Library on October 10, 2006

Prolonged Rate-Corrected QT Interval and Other Electrocardiogram Abnormalities in Girls With Turner Syndrome

Carolyn A. Bondy, Irene Ceniceros, Phillip L. Van, Vladimir K. Bakalov and Douglas R. Rosing

Pediatrics 2006;118;1220-1225
DOI: 10.1542/peds.2006-0776

This information is current as of October 10, 2006

Updated Information & Services	including high-resolution figures, can be found at: http://www.pediatrics.org/cgi/content/full/118/4/e1220
References	This article cites 25 articles, 7 of which you can access for free at: http://www.pediatrics.org/cgi/content/full/118/4/e1220#BIBL
Subspecialty Collections	This article, along with others on similar topics, appears in the following collection(s): **Endocrinology** http://www.pediatrics.org/cgi/collection/endocrinology
Permissions & Licensing	Information about reproducing this article in parts (figures, tables) or in its entirety can be found online at: http://www.pediatrics.org/misc/Permissions.shtml
Reprints	Information about ordering reprints can be found online: http://www.pediatrics.org/misc/reprints.shtml

American Academy of Pediatrics
DEDICATED TO THE HEALTH OF ALL CHILDREN™

Downloaded from www.pediatrics.org at Natl Inst Of Hlth Library on October 10, 2006